CHAPTER 43

Infection of the bones and joints

Learning objectives

To understand:

- Characteristic features of septic arthritis, acute and chronic osteomyelitis and implant infections
- Diagnostic principles in bone and joint infection
- Treatment of infection of native bones and joints
- Treatment of fracture-related and prosthetic joint infections

INTRODUCTION

Osteomyelitis is an old disease, identified in dinosaur bones, early hominids and skeletons from ancient civilisations. It is named from the components of the disease (*osteo*, bone; *myelos*, marrow; *itis*, inflammation; Greek) and is caused by bacterial invasion of the bone. Worldwide, acute infection of bones and joints remains common in children. In adults, open fractures and orthopaedic implant surgery produce a large number of severe infections each year.

Orthopaedic infection can present acutely, with major systemic upset, local inflammation and purulence, or insidiously, with gradual bone destruction leading to loss of function and slowly evolving local symptoms, with or without systemic features.

Bone and joint infections cause a substantial burden of complex morbidity. Acute infections can be life- or limb-threatening, while chronic disease may produce prolonged disability, pain and ill-health. This has major implications for patient mental health and social interactions.

EPIDEMIOLOGY

The pattern of bone infection is changing, and the incidence is increasing. Bone and joint infection affects around 1 per 10 000 children across the world. Inadequate initial treatment generates chronic infections in up to one-third of cases. In the developed world, bone infection is frequently seen after injury or surgery (contiguous focus osteomyelitis) and is often implant related (***Figure 43.1***). Increasing life expectancy, obesity, medical comorbidities (diabetes, peripheral vascular disease, immunocompromise) and increased rates of bone surgery contribute to a group of patients with increased susceptibility to infection. Prosthetic joint replacement is a highly successful therapy for joint disease but is complicated by infection in at least 1% of cases. It was estimated that joint replacement generated more than 70 000 new cases of prosthetic joint infection (PJI) in the USA in 2020. These are difficult and expensive to treat,

Figure 43.1 This open fracture of the tibia was treated with internal fixation using a plate. An early fracture-related infection developed, with skin breakdown and exposure of the metalwork.

costing over US$1.5 billion. The incidence of infection after fracture has decreased but increased use of internal fixation has increased the prevalence of post-traumatic bone infection overall. This will produce a significant economic burden for healthcare providers in the future.

Summary box 43.1

Epidemiology of bone infection

- Bone and joint infections from haematogenous spread remain common worldwide
- The increased use of implants for joint replacement and fracture fixation are an important source of new infections
- Immunocompromised patients are another increasing source (e.g. diabetes, cancer treatment)

GENERAL PRINCIPLES OF ORTHOPAEDIC INFECTION

Pathology

Bone infection has all the elements of any inflammatory condition but bone produces some specific pathological features. Acute osteomyelitis occurs when pathogenic organisms cause infection, leading to inflammation in the bone and surrounding tissues. The medullary bone may form abscesses and pus may track through the cortex to form periosteal elevation and soft-tissue extension. This process will devascularise the cortical bone, causing bone death – the characteristic feature of chronic osteomyelitis.

Bacteria can adhere to dead bone or implant surfaces, forming a complex community enveloped in a polysaccharide matrix, known as a biofilm. These bacteria alter their metabolic state, making them more resistant both to the host immune system and to antibiotics. Toxins and lytic enzymes from bacteria cause early damage to articular cartilage.

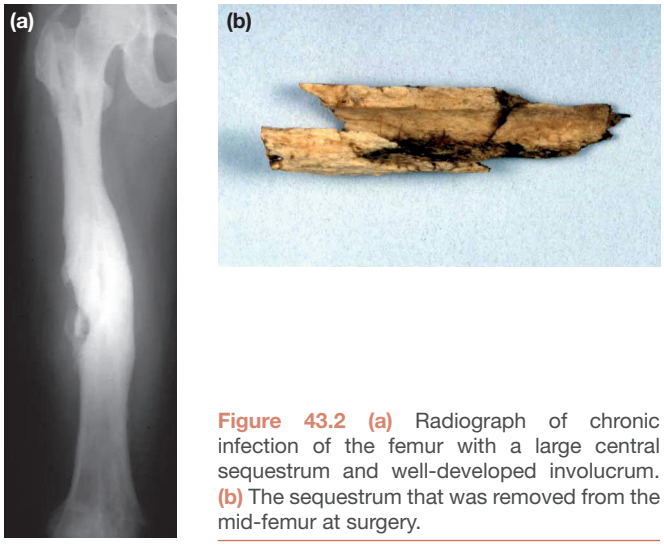

Figure 43.2 **(a)** Radiograph of chronic infection of the femur with a large central sequestrum and well-developed involucrum. **(b)** The sequestrum that was removed from the mid-femur at surgery.

The infected bone reacts to the infection by separating dead fragments of bone (sequestration) and forming sinuses to drain pus and discharge small bone fragments. New bone is laid down around the infection from the periosteum (involucrum) (***Figure 43.2***).

In septic arthritis, infection may follow direct ingress of bacteria after injury or surgery, or may result from discharge of an adjacent acute osteomyelitis into the joint. Particularly in neonates or the elderly, bacteraemia may infect a previously normal joint.

Summary box 43.2

Pathology of bone infection

- Bacteria infecting bone form a resistant biofilm on dead bone and implant surfaces
- Infected bone dies and forms a sequestrum
- The periosteum around lays down new bone – an involucrum

Microbiology

Virulent Gram-positive organisms, particularly *Staphylococcus aureus*, are the most common cause of bone or joint infection in native tissue. However, once prosthetic material is implanted, a wide range of organisms can be involved. This includes organisms with low virulence that are usually considered skin commensals, such as coagulase-negative staphylococci, α-haemolytic streptococci and *Cutibacterium acnes* (***Table 43.1***).

Diagnosis

Clinical

Diagnosis is predominantly clinical with confirmation using other tests, as outlined below.

Biomarkers

Raised inflammatory markers (erythrocyte sedimentation rate [ESR], C-reactive protein [CRP] and white cell count [WCC]) are characteristic of acute infection, but they are neither sufficiently sensitive nor sufficiently specific to rule infection in or out. Recently, new synovial fluid markers (α-defensin and calprotectin) have shown high accuracy in diagnosis of PJI.

Imaging

Plain radiographs can demonstrate dead bone, periosteal reaction, involucrum formation and loosening of implants. However, they are often normal in the first few days of infection. A normal radiograph does not exclude infection. Over time, radiographs will show progressive implant loosening, bone lysis or sequestration in chronic osteomyelitis.

Ultrasonography is ideal for identifying soft-tissue collections and joint effusions and can be used to guide bone biopsy and aspiration.

Computed tomography (CT) scans are helpful in assessing bone union of infected fractures. Small sequestra and cortical

Hans Christian Joachim Gram, 1853–1938, Professor of Medicine, Copenhagen, Denmark.

TABLE 43.1 Organisms most commonly involved in bone and joint infection.

Classification of infection	Group(s) of organisms	Examples of specific organisms and context in which infection occurs
Gram positive	Staphylococci	*Staphylococcus aureus* (commonest across all settings) Coagulase-negative staphylococci (common in implant-associated infection)
	Streptococci	α-Haemolytic streptococci, including *Streptococcus pneumoniae, Streptococcus milleri* group and *Streptococcus viridans* (in implant-associated infection)
		β-Haemolytic streptococci (e.g. *Streptococcus pyogenes, Streptococcus agalactiae*)
	Cutibacteria	Increasingly recognised in implant-associated infection and septic arthritis of the shoulder
	Enterococci	Common in diabetic foot infection and chronic osteomyelitis
Gram negative	Enterobacteriaceae	*Escherichia coli* (especially at extremes of age)
		Klebsiella spp.
		Salmonella spp. (particularly associated with sickle cell disease)
	Pseudomonas spp.	Associated with diabetic foot infections, osteomyelitis underlying chronic wounds/ulcers, patients heavily exposed to a hospital environment and/or prior antibiotics
	Kingella kingae	Common cause of septic arthritis in children under 4 years
	Haemophilus spp.	*Haemophilus influenzae* (consider in non-immunised children)
	Neisseria spp.	*Neisseria meningitidis*
		Neisseria gonorrhoeae (consider risk factors for sexually transmitted infection)
Others	Fungi, especially *Candida* spp.	Cause infection in immunocompromised and/or heavily antibiotic-exposed hosts. Common after prolonged use of negative-pressure wound therapy
	Mycobacterium tuberculosis	Present without pulmonary disease Geographical distribution Common with HIV
	Atypical mycobacteria (*Mycobacterium marinum, Mycobacterium ulcerans*)	May be a component of disseminated infection in HIV-infected patients; also cause post-surgical infection in immunocompetent hosts
Mixed	Any combination of the above organisms	More common after trauma, recurrent surgery and with poor wound healing and sinuses, or resulting from contiguous spread from an infected source (e.g. skin, GI tract)
'Culture negative'	No growth from cultures, but diagnosis of infection made on clinical/radiological/histopathological grounds	Most common in patients who have had recent antimicrobial exposure prior to surgical sampling

GI, gastrointestinal; HIV, human immunodeficiency virus.

erosions are best seen with CT and these scans can be used to plan surgery for excision of dead bone (***Figure 43.3a***).

Isotope bone scans are of very limited value as they are non-specific and give no information that may guide diagnosis or treatment. The combination of ^{18}F-fluorodeoxyglucose positron emission tomography (^{18}FDG-PET) with a CT scan allows localisation of active infection in chronic osteomyelitis and may facilitate planning of surgery. ^{18}FDG-PET/CT is not specific to infection and so cannot reliably distinguish infective from aseptic loosening around implants.

Magnetic resonance imaging (MRI) scanning is the investigation of choice, in the absence of metal implants. It is highly sensitive and specific, showing all components of the disease (***Figure 43.3b***). However, it can overestimate the extent of infection when there is widespread reactive oedema.

Microbiological diagnosis

Good treatment starts with a reliable microbiological diagnosis. Superficial swabs from wounds or spontaneously draining pus are unreliable. Cultures from these do not reflect the pathogens in the bone. Microbiological samples may be falsely negative if antibiotics are given first. Synovial tissue samples are particularly important in producing a higher diagnostic yield for infection with mycobacteria or fungi.

In chronic infections, particularly those involving prosthetic material, multiple biopsy samples are needed. It is recommended to take at least five tissue samples; each one with a separate, sterile instrument. Samples should be promptly transferred to the laboratory with clinical details of the infection. Culture should be maintained for at least 10 days in musculoskeletal infections to allow identification of slow-growing

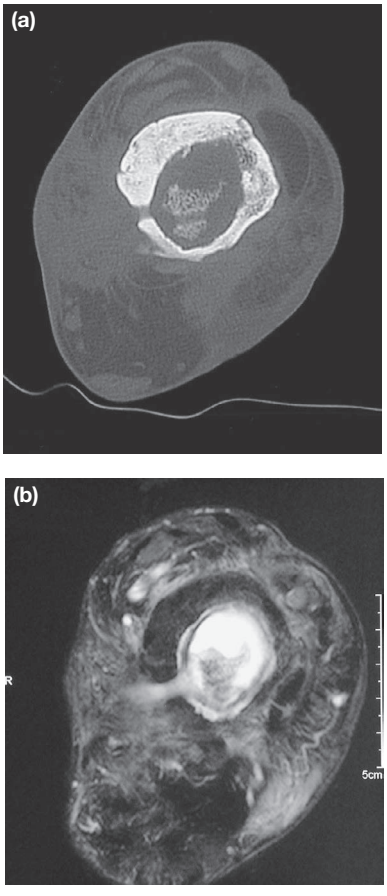

Figure 43.3 (a) Transverse computed tomography scan of the femur with a central sequestrum, sinus and cortical bone erosion. (b) Magnetic resonance imaging scan of the same femur with better resolution of the medullary infection and soft-tissue involvement.

organisms such as *C. acnes*. A positive tissue diagnosis is confirmed when phenotypically identical organisms are cultured from at least two of the five tissue samples. A single positive culture may suggest infection.

It is also possible to culture organisms from removed implants that have been subjected to ultrasonic vibration to disrupt biofilm (sonication).

Summary box 43.3

Principles of diagnosis

- ESR and CRP are neither sensitive nor specific in making a diagnosis of bone infection
- Plain radiographs may be normal in the early phase
- Ultrasonography is valuable for identifying fluid/pus collections
- MRI is usually the investigation of choice
- Superficial swabs are of no value in identifying the organism causing deep infection
- If the patient is on antibiotics, cultures may be falsely negative
- Multiple biopsy specimens should be obtained to optimise microbiological diagnosis
- A neutrophil infiltrate on histology can confirm infection

Histopathology

The histological diagnosis of infection (rather than other sources of inflammation) depends on identifying organisms on a Gram stain or the presence of a neutrophilic infiltrate. Histology can directly diagnose tuberculosis and atypical mycobacterial osteomyelitis (caseating and non-caseating granulomas), actinomycosis and fungal hyphae. The presence of five or more polymorphonuclear neutrophils per high-powered field is diagnostic in fracture-related joint infections and PJIs. Histology is valuable in confirming the presence of infection in culture-negative cases.

Management

Successful treatment requires accurate diagnosis and a multidisciplinary approach to deliver a package of care, summarised as follows:

- Preoperative:
  - patient assessment and clinical staging of disease;
  - full discussion of all treatment options with potential complications;
  - diagnostic tests for general health;
  - optimisation of patients and treatment of comorbidities.
- Operative:
  - exposure for multiple, deep bone sampling;
  - excision of all affected tissue;
  - intravenous antibiotics after sampling;
  - bone stabilisation, if necessary;
  - dead-space management;
  - soft-tissue cover, which may include plastic surgery.
- Postoperative:
  - functional rehabilitation;
  - continued antimicrobial therapy guided by culture results, with regular clinical monitoring.

The principles listed above dictate that a range of surgical and medical specialists will be needed to treat patients with bone and joint infections. If the patient is systemically well, there is often time to complete investigations, optimise patient health and plan interventions. Complex infections should be referred early to centres that specialise in these cases. Attention to diabetes control, peripheral vascular disease, nutrition and smoking cessation is essential. Many patients will benefit from psychological support or at least good counselling around the difficulties of eradicating infection and the components of treatment.

Antibiotic therapy

Patients with septic shock, or with rapidly advancing local or systemic signs of infection, should receive prompt empiric antibiotic therapy. When delay in antibiotics would be unsafe, blood cultures, local aspiration of pus or radiologically guided biopsy may give valuable culture material immediately prior to starting antibiotics.

In most cases, it is safe to delay antibiotics until definitive operative microbiological samples have been taken, particularly in chronic or implant-related infections. For patients who

have already been started on antibiotics, a clinical assessment should be made; if safe to do so, antibiotics should be stopped at least 2 weeks before biopsy or surgery.

Local guidelines should be followed, but most hospitals recommend a 'community-acquired' level of cover using an agent such as co-amoxiclav. Additional antibiotics to cover resistant Gram-positive organisms (e.g. vancomycin for methicillin-resistant *S. aureus* [MRSA]) are considered if there has been significant prior hospital exposure or if the patient is known to be colonised with these organisms. Cover for resistant Gram-negative organisms (e.g. meropenem for *Pseudomonas*) is considered in certain settings, including severe diabetic foot infection.

In the past, prolonged intravenous antibiotic courses (i.e. 4–6 weeks of treatment) were often recommended. The recent OVIVA trial has shown that oral therapy is equally effective, providing that the organism(s) is susceptible and the patient can tolerate the chosen antibiotic.

Summary box 43.4

Antibiotics for osteomyelitis

- Septic shock needs treatment without delay, with antibiotics chosen empirically based on local guidelines
- In clinically stable patients, antibiotics should be delayed until specimens have been taken
- In elective surgery for osteomyelitis, antibiotics should be stopped at least 2 weeks in advance
- Agents such as co-amoxiclav or ceftriaxone are appropriate for most community-acquired infection
- Vancomycin or meropenem may be indicated for resistant species
- Oral therapy is effective if susceptible organisms are cultured

NATIVE JOINT SEPTIC ARTHRITIS

Epidemiology

Bacterial infection of native joints occurs with an estimated incidence of 4–10 per 100 000 population per year in western Europe, with higher rates associated with socioeconomic deprivation and in developing countries. The condition most characteristically affects patients at extremes of age, usually with pre-existing arthropathy or immunocompromise (***Table 43.2***).

Joint infection may arise as a result of haematogenous dissemination of bacteria from another focus (e.g. endocarditis) or may occur as a result of direct inoculation or local extension from an infected source (e.g. traumatic wound or adjacent osteomyelitis).

Clinical features

Most patients present after an acute or subacute history with a single hot, swollen, painful joint. In children, there is often a history of recent minor trauma. The joint is held immobile in the 'position of comfort', with 'pseudoparalysis' in neonates.

TABLE 43.2 Risk factors for native joint septic arthritis.

- Extremes of age
- Underlying joint abnormality, especially rheumatoid arthritis
- Immunocompromise (e.g. diabetes mellitus, HIV infection, immunosuppressive therapy)
- Joint instrumentation (e.g. steroid injection, arthroscopy)
- Intravenous drug abuse
- Indwelling central venous catheter
- Bacteraemia (especially *Staphylococcus aureus*)

HIV, human immunodeficiency virus.

There is severe pain if any attempt is made to move the affected joint actively or passively. In children and adults, the knee joint is most frequently affected, whereas in neonates it is the hip. Fever and other systemic signs are usually present, but their absence does not rule out the diagnosis. Fever is absent in about one-third of cases.

Diagnosis

Aspiration and/or biopsy of intra-articular fluid or tissue will allow a Gram stain to be performed (although this is positive in only about one-third of infected cases). Culture of a causative organism from synovial fluid is diagnostic (positive in 80–90%) but results are delayed by the time taken to grow and identify the organism in the laboratory. A high WCC in joint fluid (e.g. 50–150 000 cells/mm^3), with a neutrophil predominance (>90%), is characteristic of infection. However, other inflammatory conditions can also cause a raised cell count, and crystals may be seen in infected joints as well as in gout or pseudogout. The limited sensitivity of direct microscopy and Gram stain and the time taken to obtain a positive culture should not delay early treatment for the infection. The decision to perform a surgical washout and give antibiotics should be based on the clinical picture.

Summary box 43.5

Presentation of septic arthritis

- Children may be toxic and febrile but adults may have only a low-grade fever
- Usually symptoms affect only one joint, often with pre-existing arthropathy
- The joint is swollen and held in a characteristic 'position of comfort'
- **Any** movement causes extreme pain

Management

Surgical management

Medical treatment alone is rarely indicated in joint sepsis. Prompt surgical drainage is a priority to avoid further damage to the cartilage. Arthroscopic washout is commonly performed but it may be difficult to remove loculated areas of infection. Washout should be with Ringer's solution or

Sidney Ringer, 1835–1910, Professor of Clinical Medicine, University College Hospital, London, UK.

0.9% sodium chloride. Antiseptics should be avoided because of the risk of chondrolysis. There should be a low threshold for open arthrotomy, particularly if a joint is not settling. A synovectomy is recommended if there is major synovial thickening, aggressive synovitis or subchondral erosions seen on radiology (Gächter stages 3 and 4). Inadequate clearance may lead to chronic infection with destruction of the joint (*Figure 43.4*). Treatment may then require joint excision, joint fusion or staged joint replacement.

Medical management

Antibiotics are usually given for 3–6 weeks (beginning with intravenous therapy). There are sparse data to guide duration. Longer courses should be considered if the infection is slow to resolve, if more than one washout is required, if the patient is bacteraemic and/or if the infection is caused by *S. aureus*. The choice of antibiotics is as given in *Summary box 43.4*.

Summary box 43.6

Native joint septic arthritis

- Most common at extremes of age, in patients with rheumatoid arthritis and in association with immunocompromise
- Most commonly affects hips in neonates and knees in adults and children
- The commonest pathogen is *S. aureus*
- Joints should be aspirated for microbiology before starting antibiotics, if safe to do so
- Management is prompt surgical joint washout, followed by 3–6 weeks of antibiotics

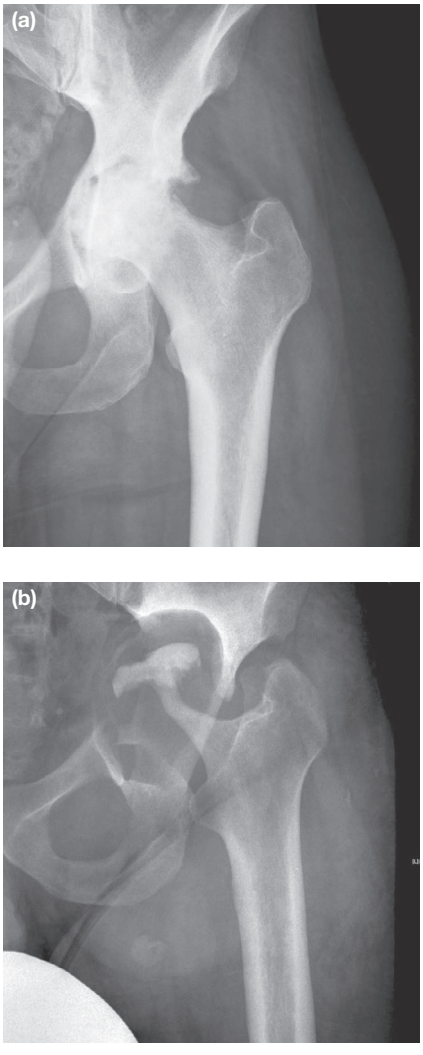

Figure 43.4 (a) Septic arthritis of the hip in a person who injects drugs. This was untreated for several weeks, resulting in destruction of the joint surface. **(b)** The same hip after 9 months without treatment. The proximal femur and acetabulum have been grossly eroded by infection.

PROSTHETIC JOINT INFECTION

Epidemiology

The incidence of PJI is around 1% per joint per year, with upper limb joints at a higher risk. Infection can be minimised with improved operative practice, prophylactic systemic antibiotics, local antibiotics in cement and the use of surgical 'care bundles'. Risk factors include obesity, skin disease, diabetes, malignancy, inflammatory arthritis, prolonged or complicated surgery, revision surgery, fracture and postoperative wound infection or haematoma.

Clinical features

PJIs may present early (within 3 months of surgery), in a delayed manner (3–24 months from surgery) or late (after 2 years).

- **Early infections** are acquired at surgery and are usually caused by virulent organisms (e.g. *S. aureus*). They present with a discharging wound, cellulitis, pain, inflammation and swelling.
- **Delayed infections** are more characteristically due to low-virulence organisms (e.g. coagulase-negative staphylococci or cutibacteria).
- **Late infections** are more likely to present with an indolent clinical syndrome of joint discomfort or mechanical dysfunction ('start-up' symptoms are particularly characteristic), with or without a discharging sinus. Late presentations are usually due to haematogenous infection of a previously uninfected joint, from bacteraemia. The source may indicate the microbiology (e.g. pneumococci from respiratory origin, *Salmonella* spp. from the gut, *Escherichia coli* from the urinary tract).

Diagnosis

Infection should be suspected in any patient with a leaking wound over an implant, unresolved pain or new pain around a previously pain-free implant. Routine blood tests may be helpful in acute infection but are often falsely reassuring.

André Gächter, contemporary, Swiss orthopaedic surgeon.

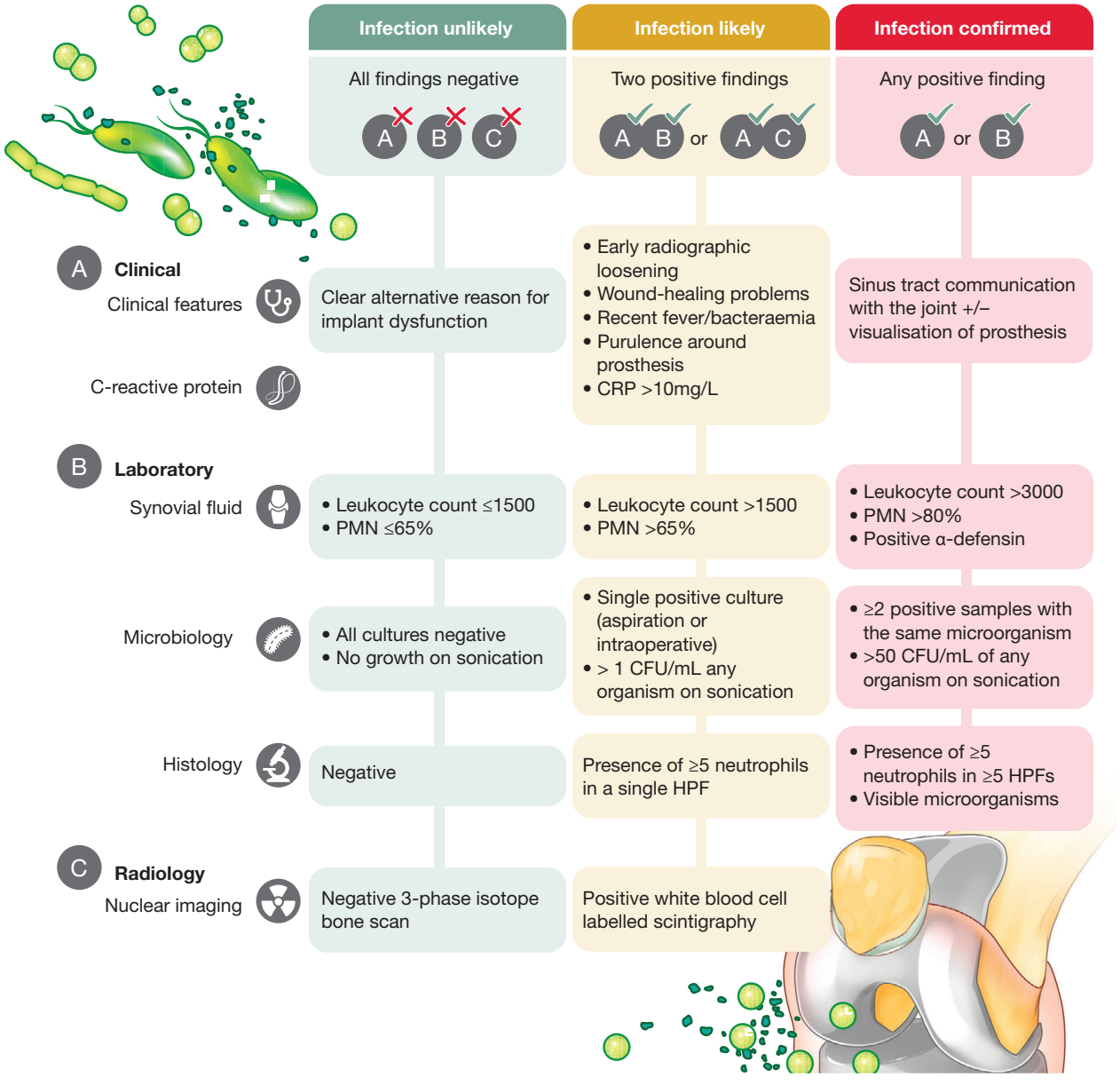

Figure 43.5 The European Bone and Joint Infection Society definition of prosthetic joint infection. CFU, colony-forming unit; CRP, C-reactive protein; HPF, high-power field; PMN, polymorphonuclear cells. (Reproduced with permission from McNally MA, Sousa R, Wouthuyzen-Bakker M *et al*. Infographic: The EBJIS definition of prosthetic joint infection: a practical guide for clinicians. *Bone Joint J* 2021; **103-B**(1): 16–17.)

The European Bone and Joint Infection Society (EBJIS) has produced diagnostic criteria for PJI. Infection is confirmed if there is a sinus communicating with the joint or there is a high synovial fluid WCC (>3000/μL), a positive microbiological culture or positive histology (more than five polymorphs per high-power field) (*Figure 43.5*) Plain radiographs may show features of loosening of a chronically infected prosthesis, and ultrasound may identify associated collections. Nuclear scans cannot reliably distinguish aseptic loosening from PJI.

Management

A multidisciplinary approach is required, including orthopaedics, plastic surgery, infectious diseases/microbiology, pharmacy, nursing, occupational therapy and physiotherapy, centred on the patient's understanding and wishes regarding their condition. Many patients have other medical comorbidities that should also be addressed and optimised. PJI can be associated with a range of emotional, psychological and mental health issues, ranging from anger about surgical complications to depression arising from chronic symptoms, lack of function and prolonged hospitalisation.

The choice of surgical strategy for prosthetic joints can be categorised as:

- salvage of an infected implant;
- removal of the infected implant with or without reimplantation.

Some groups have used the timing of presentation to determine this (i.e. salvage for early infection versus removal and revision for late infection). Others regard any firmly fixed implant as potentially salvageable, irrespective of the timing (and there are now several studies showing that this is feasible). However, it is agreed that loose infected implants should always be removed (*Figure 43.6*). Furthermore, it is essential to achieve soft-tissue cover of bone and prosthetic material. This may be difficult around the knee, requiring local muscle flaps.

Management options can be divided into the following broad approaches.

- **Debridement, antibiotics and implant retention - 'DAIR'**. This can only be undertaken if the prosthesis is well fixed. DAIR is not a form of washout as all infected soft tissue and necrotic bone must be fully excised and modular components exchanged. This cannot be achieved by arthroscopic surgery. Good soft-tissue cover is essential. Following debridement, the patient is treated with long-term antibiotics (frequently 6 weeks of intravenous therapy followed by 6 months or more of oral antibiotics). Prolonged infection-free intervals can be achieved in 80% of patients but success with this strategy may be lower in infections caused by *S. aureus* or with multiresistant organisms.
- **Two-stage joint revision surgery**. A thorough excision is undertaken and all cement and loose foreign material is removed. An antibiotic-impregnated spacer may be implanted (which may be articulating). This is a temporary measure and cannot withstand full weight-bearing. The patient is treated with oral or intravenous antibiotics, most commonly for 6 weeks. A new prosthesis is implanted after the course of antibiotics has been completed. In recent years there has been a trend towards shorter intervals between stages, often within the 6-week antimicrobial therapy.
- **Single-stage joint revision surgery**. The procedure is the same as above, but removal and reimplantation are undertaken in the same operating session. Healthy soft tissues around the new implant are essential to prevent reinfection. Some centres consider single-stage revisions when less florid signs of infection are present (i.e. absence of collections or sinus tracts), or for frail patients for whom the risk of a second operation is higher. There are no adequate trial data comparing outcomes with the two-stage approach.
- **Joint removal or fusion**. When reconstruction options are not technically possible or are ruled out by comorbid conditions, removal of the prosthesis without reimplantation may palliate symptoms. An example is the Girdlestone excision arthroplasty of the hip. In prosthetic infections of the knee, ankle or wrist, it may be possible to create a joint fusion after prosthesis removal. This is complex surgery, which may involve major bone reconstruction. Amputation may be necessary for knee or ankle implants.
- **Suppressive therapy with antibiotics**. In patients who are not medically fit for any operative intervention, or who choose to decline all surgical options, long-term treatment with antibiotics may help to suppress the symptoms of infection. There are limited data, but anecdotally the success rate of this approach is low.

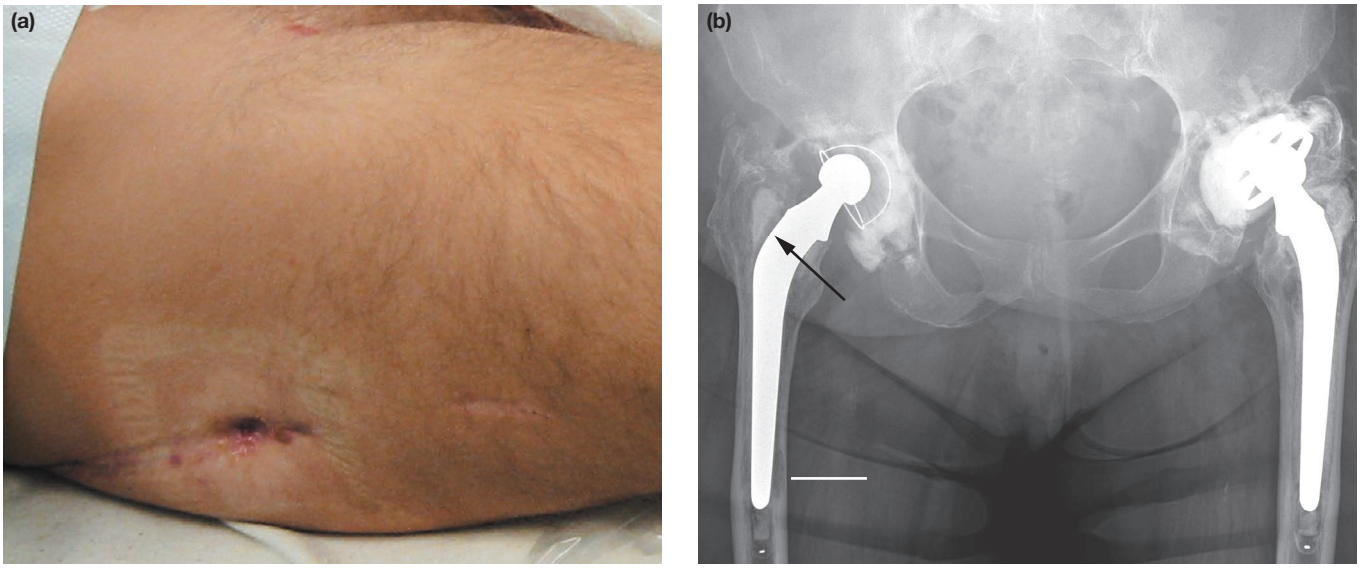

Figure 43.6 (a) Sinus draining from the scar over the lateral side of the hip. This patient had a total hip replacement 14 years before that had been complicated by a wound haematoma and infection. (b) Radiograph of both hips of same patient. Both hips are loose but only the right side has definite infection (arrows).

Gathorne Robert Girdlestone, 1881–1950, Nuffield Professor of Orthopaedics, University of Oxford, UK, described excision arthroplasty of the hip for septic arthritis.

Summary box 43.7

Prosthetic joint infection

- Well-fixed prostheses may be Debrided, treated with Antibiotics and the Implant Retained ('DAIR' approach)
- Loose prostheses must be removed
- Replacement can be made at the initial surgery (one stage) or after a delay to allow infection to be eradicated with antibiotics (two stage)
- Multiple surgical samples are crucial for identifying a pathogen
- Thorough excision of infected tissue is a key determinant of outcome
- Long-term antibiotics may be used for patients who are not suitable for major revision surgery

FRACTURE-RELATED INFECTION

Infection complicates around 3–5% of all fracture fixations. Open tibia fractures are a high-risk group with up to 25% becoming infected after fixation. Calcaneal fractures and ankle fracture fixation in the elderly also have high infection rates.

Many of the principles outlined above for PJI can be applied to infections associated with metalwork used to fix fractures.

There are several clinical scenarios which must be addressed:

- **Unhealed fracture with *stable* fixation**. This is usually seen early after fixation and can be managed with deep sampling, debridement of infected tissues and management of dead spaces (often with local antibiotic carriers) ('DAIR' approach). It is extremely important to provide good soft-tissue cover over the fracture. In the tibia, this will most often require a plastic surgical reconstruction. After debridement, systemic antibiotics must be given to suppress infection until bone union.
- **Healed fracture with infected implant**. In these cases, the implant can be removed, but there should still be a careful debridement, deep sampling, dead space management and soft-tissue cover.
- **Unhealed fracture with *unstable* fixation**. Stability is essential for bone healing and eradication of infection. If the implant is not stable, it should be removed and replaced by an external fixator. Radical excision of the infected fracture is needed and the resulting defect may present a major reconstructive challenge (*Figure 43.7*). Recently, antibiotic-coated locking nails have been used to restabilise infected fractures with some success.

ANTIMICROBIAL THERAPY FOR PROSTHETIC JOINT INFECTION AND FRACTURE-RELATED INFECTION

Following surgical sampling, empiric broad-spectrum intravenous antibiotic therapy (e.g. vancomycin and meropenem) should be given. This can be rationalised when culture results are available. In culture-negative cases, ongoing therapy to cover the most likely pathogens should be instituted.

The duration of therapy is determined according to the surgical approach, with 6 weeks for those in whom prosthetic material is completely removed versus 6 months for patients undergoing a 'DAIR' strategy, and prolonged (occasionally lifelong) treatment for patients in whom all other options are contraindicated or intolerable. In a few patients, the best therapy is no intervention, when chronic low-grade symptoms are well controlled and preferable to the risks of either surgery or long-term antibiotic therapy.

The antibiotic regimen should be planned with the advice of a microbiologist and supervised carefully to promote compliance and to detect and manage side effects. Monitoring of the joint is largely on clinical grounds; biomarkers including CRP are not predictive of treatment failure. Serial radiographs are helpful to detect progressive bone loss, which may be an indicator of recurrent active infection and can predispose to periprosthetic fracture and implant loosening.

ACUTE OSTEOMYELITIS

This presents like septic arthritis with a short history of pain, swelling, loss of function and systemic upset. In adults, the vertebral column is the commonest site; in children, long bones are most frequently affected. In young children, a fever and refusal to weight-bear may be the only clues.

Diagnosis

In the early phase (2–3 days) radiographs may be normal but MRI will show bone oedema and periosteal elevation. After 5–7 days, plain radiographs may show subtle abnormality with osteopenia and periosteal new bone formation. WCC and CRP are often elevated in the early phase. Treatment should not be delayed pending investigations.

Management

Acute osteomyelitis can be treated with antibiotics alone, when the diagnosis is made within 2–3 days of onset of symptoms, there is no dead bone on imaging and there is no adjacent septic arthritis. Culture results help to guide therapy, so blood cultures should be taken, and radiologically guided sampling should be considered. Empirical intravenous therapy against Gram-positive organisms is given (cephalosporins or flucloxacillin), adding gentamicin to cover Gram-negative organisms in children under 1 year.

The limb should be splinted and good analgesia given. Intravenous antibiotics should be converted to oral therapy, depending on clinical progress and the results of cultures, and therapy is continued for a total of 2–3 weeks. If the patient does not respond rapidly, if the limb deteriorates or if there is imaging evidence of progression of disease, surgery is indicated to prevent bone destruction and the onset of chronic osteomyelitis.

With prompt treatment, acute bone infection has a good prognosis with a 90% cure rate. Failure to treat adequately produces chronicity, with recurrent infection over many years. In children, the adjacent growth plates and joints may be affected with subsequent deformity and joint destruction.

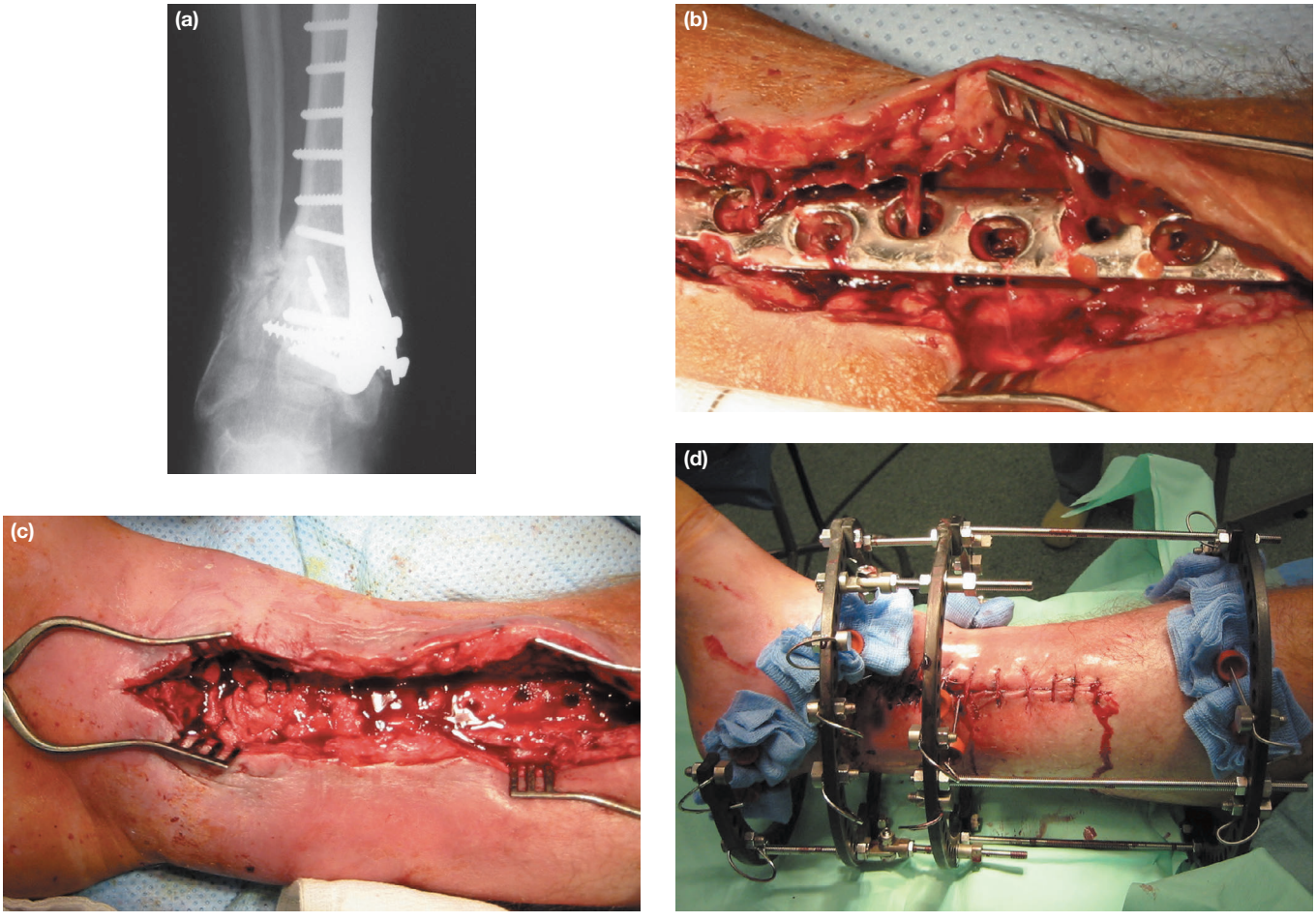

Figure 43.7 (a) Radiograph of a complex distal tibia fracture that was internally fixed but complicated by deep infection. (b) At operation, the plate was loose and grossly infected. (c) The plate and all infected tissue was excised. Deep samples were sent for microbiology and histology. The defect at the lower end was filled with an absorbable antibiotic carrier. (d) The bone was stabilised with an Ilizarov circular external fixator and the skin primarily closed.

Summary box 43.8

Acute osteomyelitis

- Presents in children with toxaemia, fever and unwillingness to move the limb
- May affect the vertebral column in adults, where back pain may be the only symptom
- Radiographs may be normal for up to 1 week so are of limited value in early diagnosis
- MRI is the investigation of choice
- WCC and CRP are usually raised
- Early diagnosis is treated with high dose intravenous antibiotics, started empirically and modified with culture results
- Late diagnosis and/or failure of medical treatment requires surgical debridement

CHRONIC OSTEOMYELITIS

This is a serious condition that may affect the patient for decades. Chronic bone infection is best treated within a dedicated multidisciplinary team that has the skills to deal with all aspects of the condition, the associated comorbidities and the range of surgical reconstructive options.

Diagnosis

Plain radiographs can delineate soft-tissue swelling, subperiosteal reaction, bone destruction and sequestra. CT scans are good for cortical bone imaging (*Figure 43.8*). MRI is the imaging test of choice (see *General principles of orthopaedic infection*). Blood tests are often normal in chronic osteomyelitis. Confirmation of the diagnosis is with culture from deep surgical samples and histology. ^{18}FDG-PET CT scanning can be helpful for surgical planning.

Gavriil Abramovich Ilizarov, 1921–1992, orthopaedic surgeon, Kurgan, Western Siberia, Russia, pioneered this eponymous approach to bone reconstruction in the 1960s for the management of osteomyelitis, fractures and limb deformities.

Figure 43.8 (a) Coronal computed tomography scan of the femur showing diaphyseal chronic osteomyelitis. **(b)** A transverse section clearly shows the sequestration of the lateral cortex and overlying new bone formation (involucrum).

Management

The BACH classification divides patients into 'uncomplicated', 'complex' and 'limited options available' based on the four important features of the infection (*Figure 43.9*). These are: the anatomical location in the bone (B), the antimicrobial profile (A), the need for soft-tissue cover (C) and the health of the host (H). Treatment must always address all four parts of the classification to achieve good outcomes. All infected unhealed fractures and infected non-unions are complex.

As with PJI, comorbidities should be optimised before surgery. The interaction between the patient's health status and the extent of the bone infection greatly affects the outcome after surgery. In chronic infection, it is essential to address medical conditions that may impair wound healing (e.g. smoking, peripheral vascular disease, diabetes, steroid use) prior to surgery. This approach has been shown to improve cure rates. A joint assessment by an orthopaedic surgeon, plastic surgeon and infectious disease physician will allow good preoperative planning.

	Bone involvement	**A**ntimicrobial options	**C**overage of soft tissue	**H**ost status
Uncomplicated	B1 Cavitary involvement (including medullary, cortical and non-segmental corticomedullary)	Ax Unknown/culture negative A1 <4 resistant tests ≥80% susceptibility tests sensitive	C1 Direct closure possible Plastic surgery expertise *not required*	H1 Patient fit and well or has well-controlled disease
Complex	B2 Segmental involvement Any infection with joint involvement	A2 >4 resistant tests <80% susceptibility tests sensitive	C1 Direct closure not possible Plastic surgery expertise *required*	H2 Patient with either poorly controlled disease, severe disease or recurrent osteomyelitis
Limited options	B3 Whole bone involvement	A3 Sensitivity to either 0 or 1 susceptibility test		H3 Unfit for anaesthetic Patient declines surgery Surgery not indicated

Figure 43.9 The BACH classification of osteomyelitis.

Figure 43.10 (a) This magnetic resonance imaging scan shows a BACH uncomplicated medullary osteomyelitis of the femur. (b) The infected bone has been removed by reaming and the central defect filled with absorbable calcium sulphate pellets with gentamicin.

In uncomplicated disease, excision of the dead bone, with local and systemic antibiotics and direct wound closure, is highly effective (*Figure 43.10*). If more than one-third of the cortical circumference is excised, splintage is essential, often with external fixation to prevent fracture. Secondary bone grafting may be needed.

When the infection is segmental (BACH complex), or when the soft-tissue envelope cannot be closed directly, major reconstruction will be required. Curative resection must be segmental and bone stabilisation will always be required. The Ilizarov method, which uses distraction osteogenesis to fill bone defects, is a powerful and successful technique in these cases. It can be combined with free tissue transfer. This allows reconstruction to proceed in parallel with rehabilitation.

After surgery, patients should be given antibiotics. In total segmental excision of infection a short course may be indicated, but in most chronic infections 6–12 weeks is often advised. If there is any doubt about the adequacy of removal of the dead bone, a long antibiotic course will be needed and recurrence will be more likely. In chronic fracture-related infection, antibiotics should continue until fracture union.

There is now increasing interest in the use of local antibiotic absorbable carriers. These can deliver high doses of antibiotics into the bone, without systemic effects. Some ceramic materials (with hydroxyapatite) can form new bone in the defect, avoiding the need for secondary bone grafting.

Summary box 43.9

Chronic osteomyelitis

- Chronic disease requires specialist surgery with excision, stabilisation and reconstruction
- Host status should be optimised before surgery
- Following surgery, antibiotic therapy is typically continued for at least 6 weeks

DIABETIC FOOT INFECTION

The global prevalence of diabetes has increased exponentially in recent years. Foot infections are a leading cause of hospital admissions in this group, with an annual incidence of foot complications of 1–2% per year owing to the combined influence of macro- and microvascular insufficiency, mechanical disruption, peripheral and autonomic neuropathy, immune defects and impaired tissue healing. Ulceration of the calcaneum and bones of the forefoot is common (*Figure 43.11*) and will result in amputation in up to one-fifth of cases.

Infection begins as invasion of bacteria into the compromised tissues and will rapidly spread to deep structures. Diagnosis is made on the clinical signs and symptoms of local inflammation and systemic upset. The presence of a wound/ulcer, spreading cellulitis, fevers or critical ischaemia indicate a more severe infection and the need for urgent treatment.

Blood tests are frequently unhelpful, as inflammatory markers may be normal or only mildly raised. Plain radiographs may show evidence of osteomyelitis but can be normal (particularly early in infection). MRI is the most sensitive imaging modality for diagnosis of bone involvement. Superficial swabs

Figure 43.11 A severe diabetic foot infection, with marked infection, necrosis and tissue loss. The patient was neuropathic and had ankle and hindfoot deformity. The foot was salvaged with a corrective triple fusion of the hindfoot, excision of the infected ulcer, antibiotic therapy and primary closure of the lateral soft tissues.

or cultures from ulcers or sinus tracts are not reliable in determining the organisms responsible for underlying deep-seated infection. A combination of the 'probe-to-bone' test with elevated inflammatory markers and abnormal plain radiographs confirms the diagnosis.

The aetiological agents of diabetic foot infection are the same as for bone infection in non-diabetic individuals, namely *S. aureus*, β-haemolytic streptococci and aerobic Gram-negative bacilli. *Pseudomonas* is over-represented, and empirical therapy for severe infections should include cover for this organism. Anaerobes may also be present and addition of metronidazole (particularly for abscesses and/or devitalised tissue) should be considered.

Surgical debridement is required for collections, necrotic areas or more extensive osteomyelitis. Thought should be given to distinguishing superficial osteitis, resulting from loss of soft-tissue cover (often in association with vascular compromise), from more extensive bone involvement. In the former, biopsy and antibiotic therapy may be of limited importance and optimising glycaemic control, improving vascular supply and relieving pressure, with appropriate footwear, much more important. This approach may avoid more extensive tissue loss or later amputation.

Many patients with diabetes with foot infection have significant vascular compromise and neuropathy, which makes healing after surgery unreliable. A full vascular assessment is mandatory in those with poor peripheral pulses. Proximal angioplasty or bypass surgery may improve distal vascularity to a level where infection surgery in the foot may be more successful.

Amputation is not an easy option in diabetic foot disease and wound healing can be problematic. In general, excision should be adequate to remove all infected material and excess bone may need to be resected to allow tension-free skin closure. If there is extensive peripheral neuropathy, a below-knee amputation in an area with better sensation may be more appropriate.

Summary box 43.10

Diabetic foot infection

- The most important risk factor for osteomyelitis is the presence of a foot ulcer
- Ulcer swabs are not reliable in determining the pathogens responsible for osteomyelitis
- Bone biopsy for culture should be considered in extensive/complex infection but may not be necessary in mild disease
- In severe disease, surgical debridement of collections and/or necrotic tissue is required, followed by antibiotics tailored according to culture results

MUSCULOSKELETAL INFECTION CAUSED BY MYCOBACTERIA

Tuberculous arthritis/osteomyelitis remains prevalent in low- and middle-income countries. There is now a resurgence across the world as a consequence of migration and immunocompromise (including human immunodeficiency virus [HIV]). The most common organism is *Mycobacterium tuberculosis*. Around half of all cases affect the spine, typically manifesting as para-discal infection but also causing discitis and vertebral osteomyelitis. Native joint infection typically presents with monoarticular pain in a weight-bearing joint.

For optimal management of tuberculosis, the patient must be referred to a specialist multidisciplinary team for input that includes the following components.

- Baseline screening for HIV and other blood-borne viruses.
- Assessment for other sites of mycobacterial infection.
- Measurement of baseline renal and liver function, to be repeated at intervals throughout treatment. Drug-induced hepatitis is the commonest serious side effect that may require temporary withdrawal or alteration of therapy.
- Baseline and follow-up testing of hearing (if injectable agents to be used) and colour vision (if ethambutol to be used).
- Consideration of any potential drug interactions (rifampicin is a potent inducer of the cytochrome P450 system; it can interact with many classes of drug, including anticonvulsants, antiretroviral therapy, anticoagulants, antibiotics and antifungals).
- Institution of appropriate infection control precautions and contact tracing.
- Appropriate education and support to optimise adherence to therapy.
- Prescription of an appropriate combination of drug therapy.
  - For fully sensitive *M. tuberculosis*, the preferred regimen is oral rifampicin, isoniazid, pyrazinamide and ethambutol for 2 months, followed by rifampicin and isoniazid for a further 4 months.
  - Worldwide, there is an increase in the prevalence of drug-resistant tuberculosis, classified as multidrug resistant (MDR) and extensively drug resistant (XDR). Infection with these organisms requires a treatment regimen that includes an injectable agent (typically amikacin, kanamycin or capreomycin) together with oral agents selected according to the susceptibility profile of the isolate (these may include cycloserine, ethionamide, para-aminosalicylic acid [PAS], fluoroquinolones and linezolid). Prolongation of therapy is required, and side effects/toxicity are common.
- Surgery is only recommended to decompress or stabilise the spine and occasionally to confirm the diagnosis by tissue biopsy.

Non-tuberculous mycobacteria are ubiquitous environmental organisms. They are best recognised as agents of disease in patients with underlying immunocompromise (including HIV, diabetes and organ transplantation) or other risk factors for introduction of infection (such as penetrating trauma or the presence of a prosthesis). However, they may occasionally also cause infection in hosts without obvious risk factors.

Treatment can be difficult; these organisms are resistant to the standard agents used for first line antituberculous therapy; surgery to debride and drain sites of infection can therefore be particularly important to reduce the bacterial burden. There is no single standardised drug regimen or duration, so choice of

therapy depends on the *in vitro* susceptibility of the organism and length of treatment depends on the location of disease; extent of surgical debridement; the identification and phenotypic characteristics of the organism; and the patient's underlying condition, presence of immunocompromise and response to therapy. As for treatment of *M. tuberculosis*, expert medical oversight is crucial throughout treatment.

ACKNOWLEDGEMENTS

Dr Philip Bejon and Dr Philipa Matthews contributed to earlier versions of this chapter, and I remain grateful for their input.

FURTHER READING

Coakley G, Mathews C, Field M *et al.* BSR & BHPR, BOA, RCGP and BSAC guidelines for management of the hot swollen joint. *Rheumatology* 2006; **54**: 1039–41.

Dudareva M, Hotchen AJ, Ferguson J *et al.* The microbiology of osteomyelitis: changes over ten years. *J Infection* 2019; **79**: 189–98.

Ferguson J, Athanasou N, Diefenbeck M, McNally MA. Radiographic and histological analysis of a synthetic bone graft substitute eluting gentamicin in the treatment of chronic osteomyelitis. *J Bone Joint Infect* 2019; **4**(2): 76–84.

Hotchen AJ, Dudareva M, Corrigan RA *et al.* Can we predict outcome after treatment of long bone osteomyelitis? A study of patient-reported quality of life, stratified with the BACH classification. *Bone Joint J* 2020; **102-B**(11): 1587–96.

Iliadis AD, Ramachandran M. Paediatric bone and joint infection. *EFORT Open Rev* 2017; **2**(1): 7–12.

Li H-K, Rombach I, Zambellas R *et al.* Oral versus intravenous antibiotics for bone and joint infection. *N Engl J Med* 2019; **380**: 425–36.

Lipsky BA, Senneville E, Abbas ZG *et al.* Guidelines on the diagnosis and treatment of foot infection in persons with diabetes (IWGDF 2019 update). *Diabetes Metab Res Rev* 2020; **36**(S1): e3280.

McNally MA. Osteomyelitis. In: Chen AF (ed.). *Management of orthopaedic infections: a practical guide.* New York, NY: Thieme, 2021: ch. 5, 61–87.

McNally MA, Ferguson JY, Lau ACK *et al.* Single-stage treatment of chronic osteomyelitis with a new absorbable, gentamicin-loaded, calcium sulphate/hydroxyapatite biocomposite. *Bone Joint J* 2016; **98-B**: 1289–96.

McNally M, Govaert G, Dudareva M *et al.* Definition and diagnosis of fracture-related infection. *EFORT Open Rev* 2020; **5**: 614–19.

McNally MA, Sousa R, Wouthuyzen-Bakker M *et al.* The EBJIS definition of prosthetic joint infection: a practical guide for clinicians. *Bone Joint J* 2021; **103-B**(1): 18–25.

Metsemakers W-J, Morgenstern, M, Senneville E *et al.* General treatment principles for fracture-related infection: recommendations from an international expert group. *Arch Orthop Trauma Surg* 2020; **140**(8): 1013–27.

Middleton R, Khan T, Alvand A. Update on the diagnosis and management of prosthetic joint infection in hip and knee arthroplasty. *Bone Joint 360* 2019; **8**(4): 5–13.

Mifsud M, Ferguson JY, Stubbs DA *et al.* Simultaneous debridement, Ilizarov reconstruction and free muscle flaps in the management of complex tibial infection. *J Bone Joint Infect* 2020; **6**: 63–72.